

# Male Reproductive system

Md. Noor Raman(Asst.Prof.NENC)

# 1. MALE REPRODUCTIVE SYSTEM

The reproductive system of both males and females consists of primary (or essential) organs and secondary (or accessory) organs.

primary organs are referred to as “Gonads”. (The female gonads are the ovaries, the male gonads are the testes.)

➤ The primary function /responsibility of the gonads is secretion of hormones and production of gametes (ova & sperm.)

## **Male reproductive system**

The primary roles of the male reproductive system are:

- Production and transportation of sperm.
- Deposit of sperm in the female reproductive tract and
- Secretion of hormones

## PARTS OF MALE REPRODUCTIVE SYSTEM

The external structures of male reproductive system include:

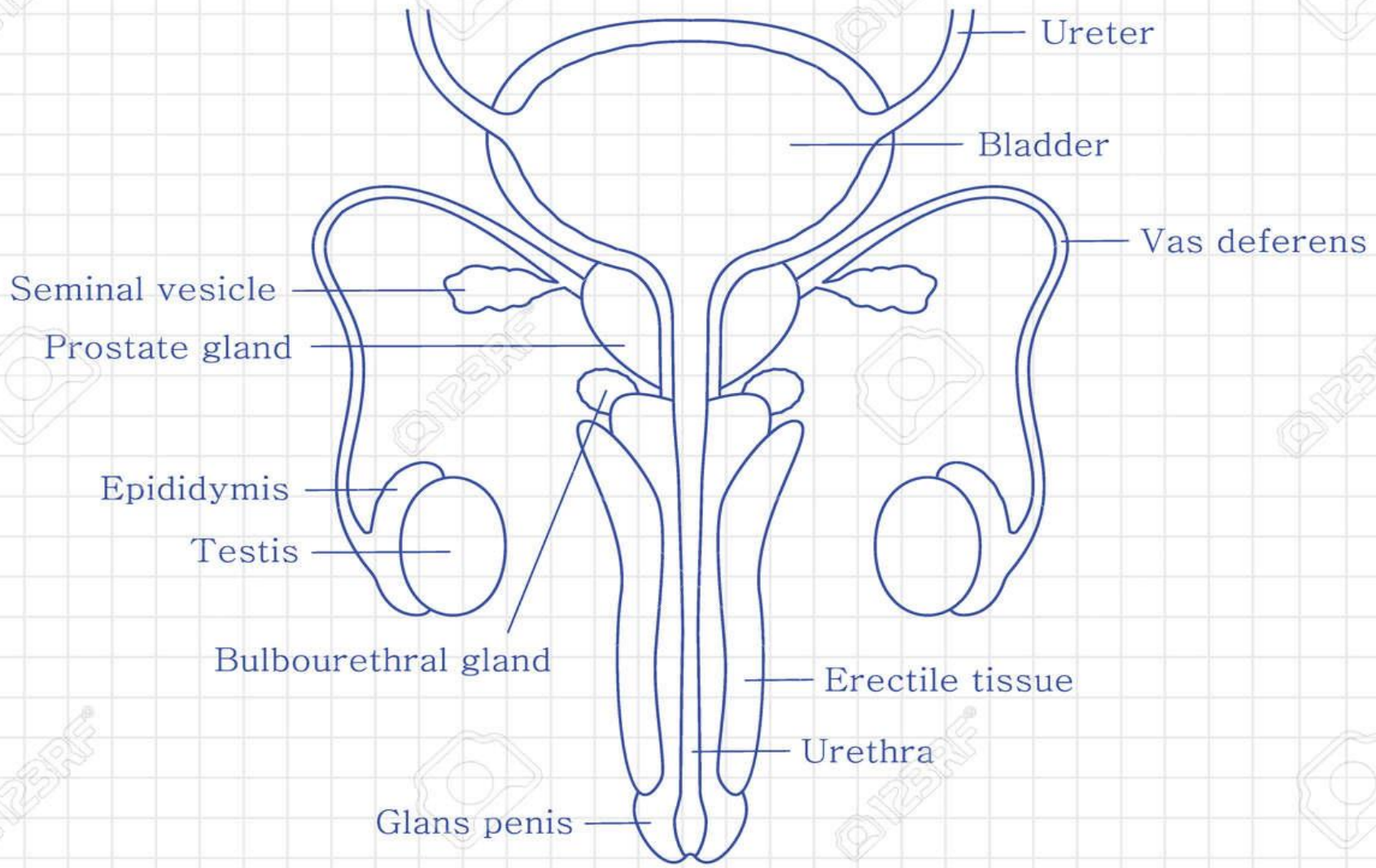
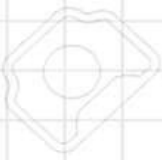- The penis
- The scrotum
- The testicles & Epididymis

The internal organs of the male reproductive system include the following:

- Vas deferens
- Ejaculatory ducts
- Urethra
- Seminal vesicles
- Prostate gland
- Bulbourethral glands

Q123RF®

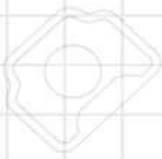Q123RF®



Q123RF®

Q123RF®

Q123RF®



# Male Reproductive System

